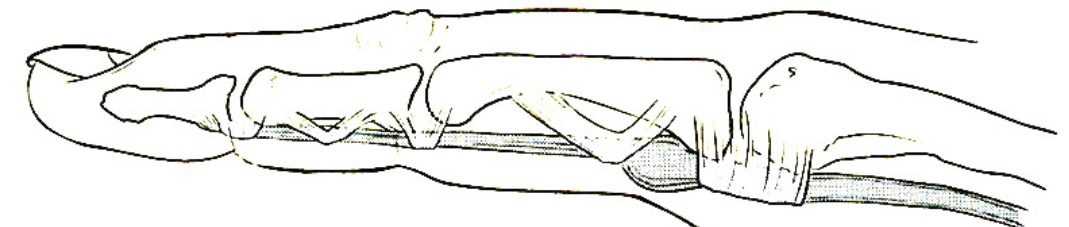
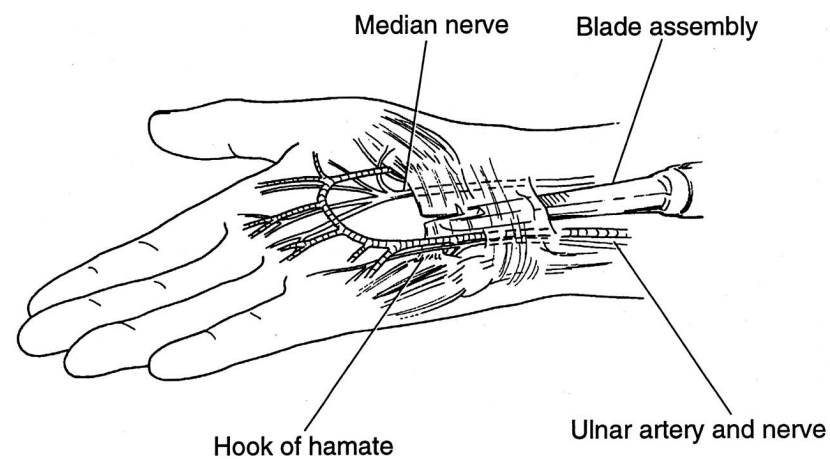
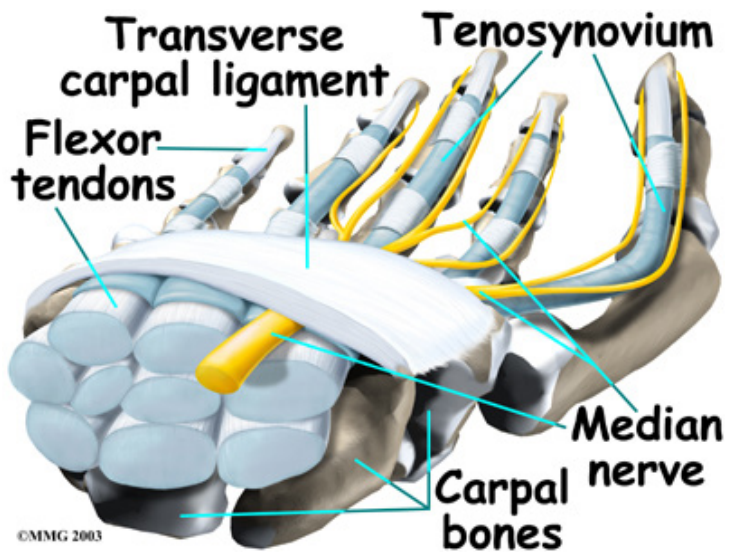
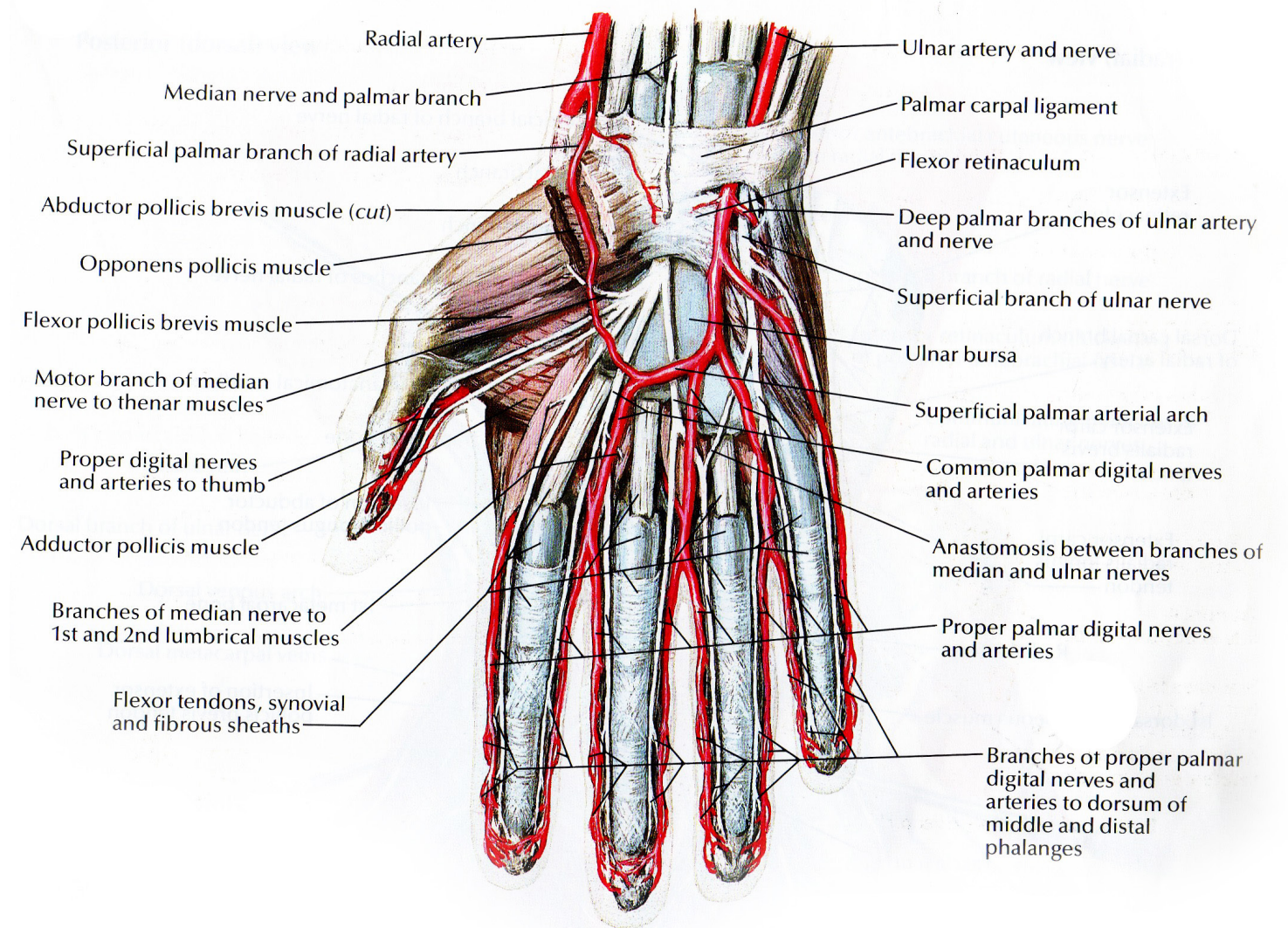
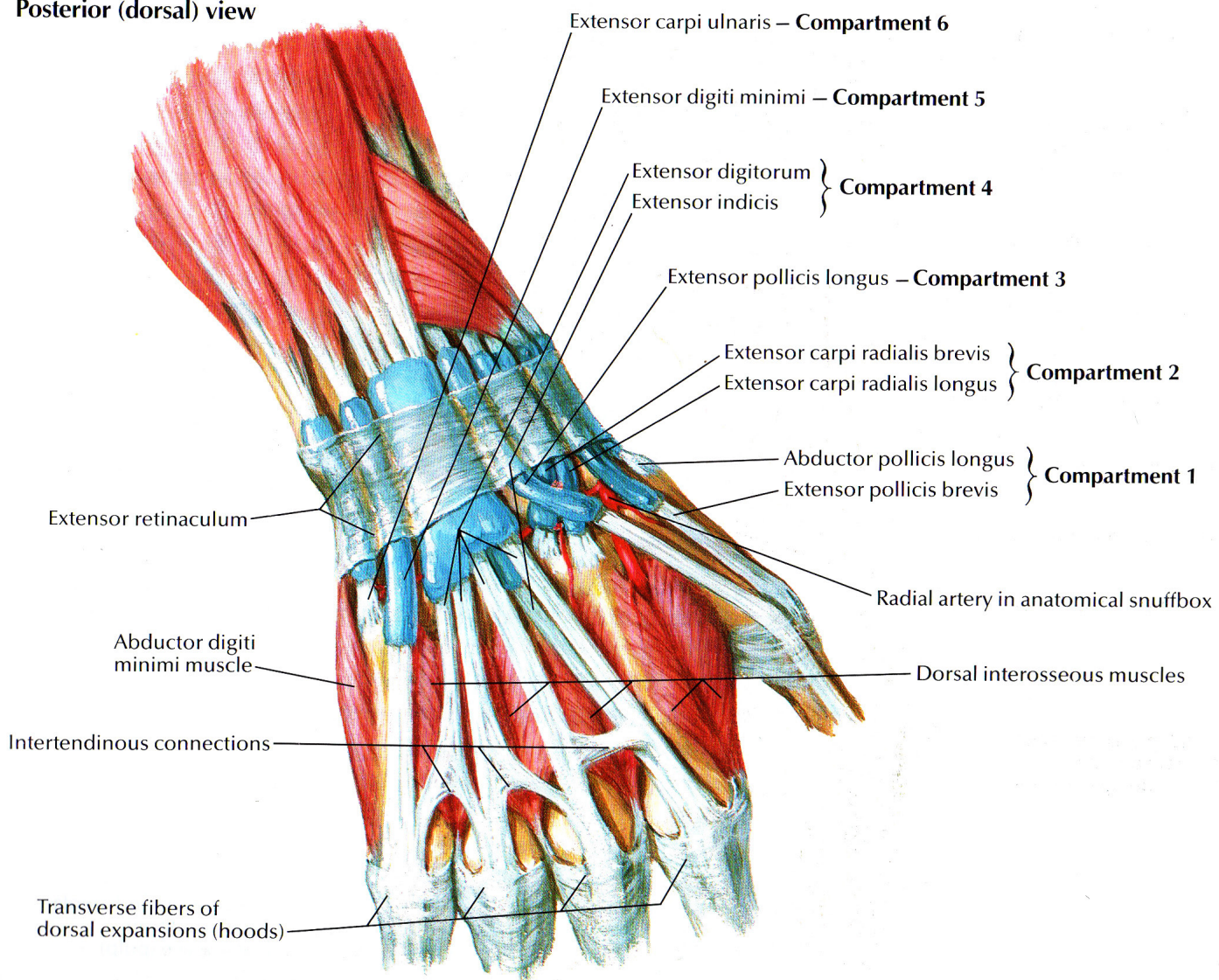
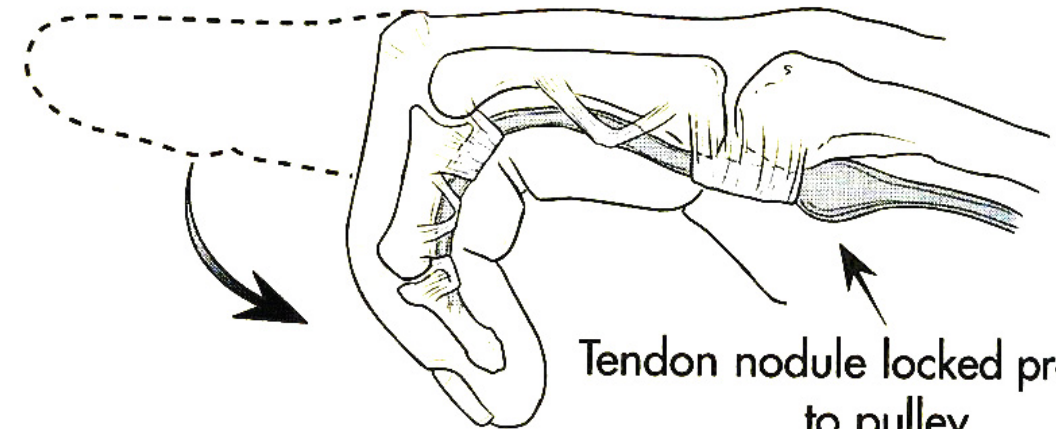


**Posterior (dorsal) view**



Nodule distal to pulley with finger in extension



Tendon nodule locked proximal to pulley

