

## Hip FAI Patient Education

**Kyle Flikkema, MD**

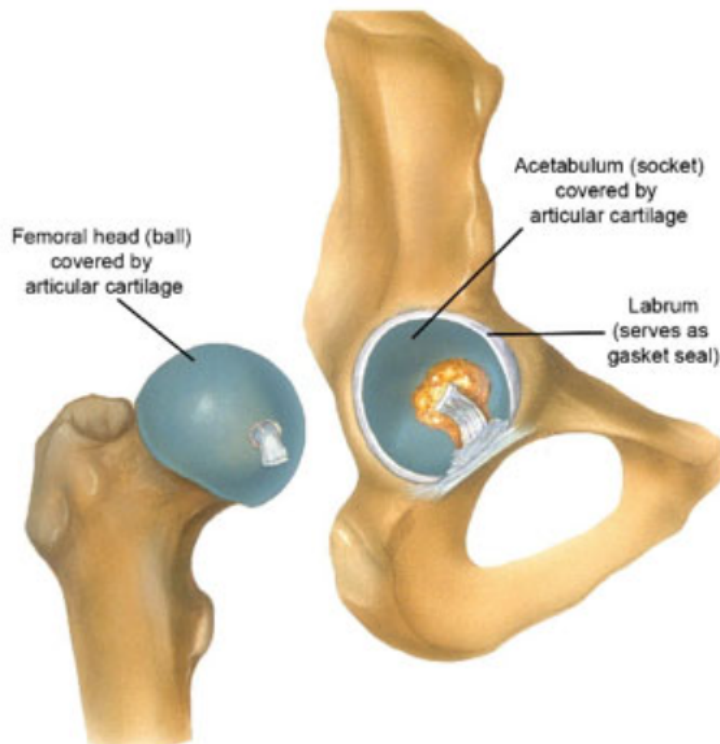Phone: 763-786-9543 | Website: TCOmn.com

### WHAT IS FAI (FEMORAL ACETABULAR IMPINGEMENT)?

FAI is a condition in which extra bone forms along one or both of the bones that form the hip joint — giving the bones an irregular shape. Because they do not fit together perfectly, the bones rub against each other during movement. Over time this friction can damage the joint, causing pain and limiting activity.

### HIP ANATOMY

The hip is a ball-and-socket joint. The socket is formed by the acetabulum, which is part of the pelvis. The ball is the femoral head, which is the upper end of the femur (thighbone). The ball and socket are both covered with smooth articular cartilage that allows for near frictionless movement of the hip joint. The socket is then surrounded by the labrum. The labrum is a ring of cartilage that sits circumferentially around the edge of the socket and forms an “O-ring” or gasket seal for the ball-and-socket joint. In FAI, the labrum and articular cartilage are the two main structures that can be damaged, causing pain and eventually leading to arthritis.



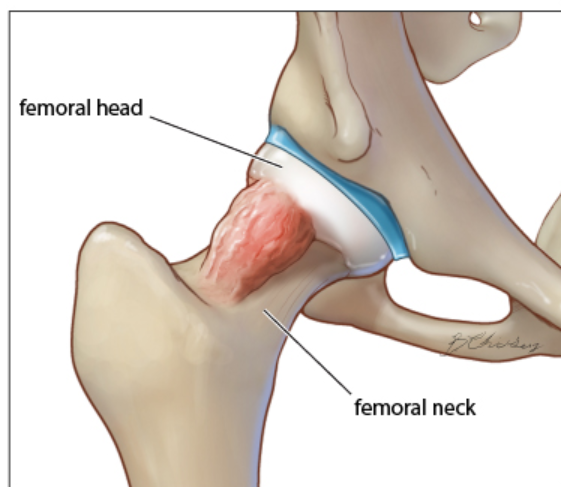
## TYPES OF FAI

In FAI, the abnormally shaped ball and/ or socket causes abnormal contact. This contact, i.e. “impingement,” of the bones can result in tears of the labrum and the breakdown of articular cartilage.

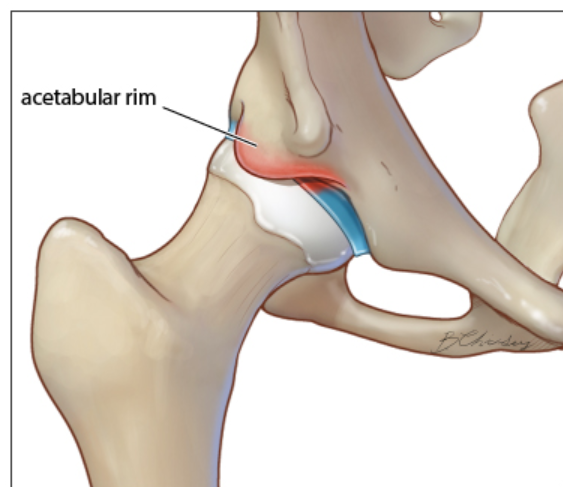
There are three types of FAI: cam, pincer, and combined impingement.

- Cam: In cam impingement, the femoral head is not round and cannot rotate smoothly inside the acetabulum. A bump forms on the edge of the femoral head that grinds the cartilage inside the acetabulum.
- Pincer: This type of impingement occurs because extra bone extends out over the normal rim of the acetabulum. The labrum can be crushed under the prominent rim of the acetabulum.
- Combined: Combined impingement means that both the pincer and cam types are present.

**Cam impingement**



**Pincer impingement**



Illustrations Copyright 2016 Regents of the University of Colorado. All Rights Reserved. Created by Berrien Chidsey, models created by Nathan Billington.

## WHAT CAUSES FAI?

FAI occurs because the hip bones do not form normally during the childhood growing years. FAI is thought to be something that develops during growth, while the effects of it are often not realized until later in life. It is important to know that not all those that develop these abnormal bony shapes develop symptoms.

## SIGNS AND SYMPTOMS

Pain in the groin or hip (front, side and/or back) aggravated by activity and/or prolonged sitting is the most common symptom of FAI. Other signs or symptoms include difficulty flexing the hip and popping or clicking of the hip.

## DIAGNOSIS

FAI is diagnosed using the combination of the patient’s symptoms, physical exam maneuvers, imaging findings and possibly diagnostic injections.

### Physical Exam:

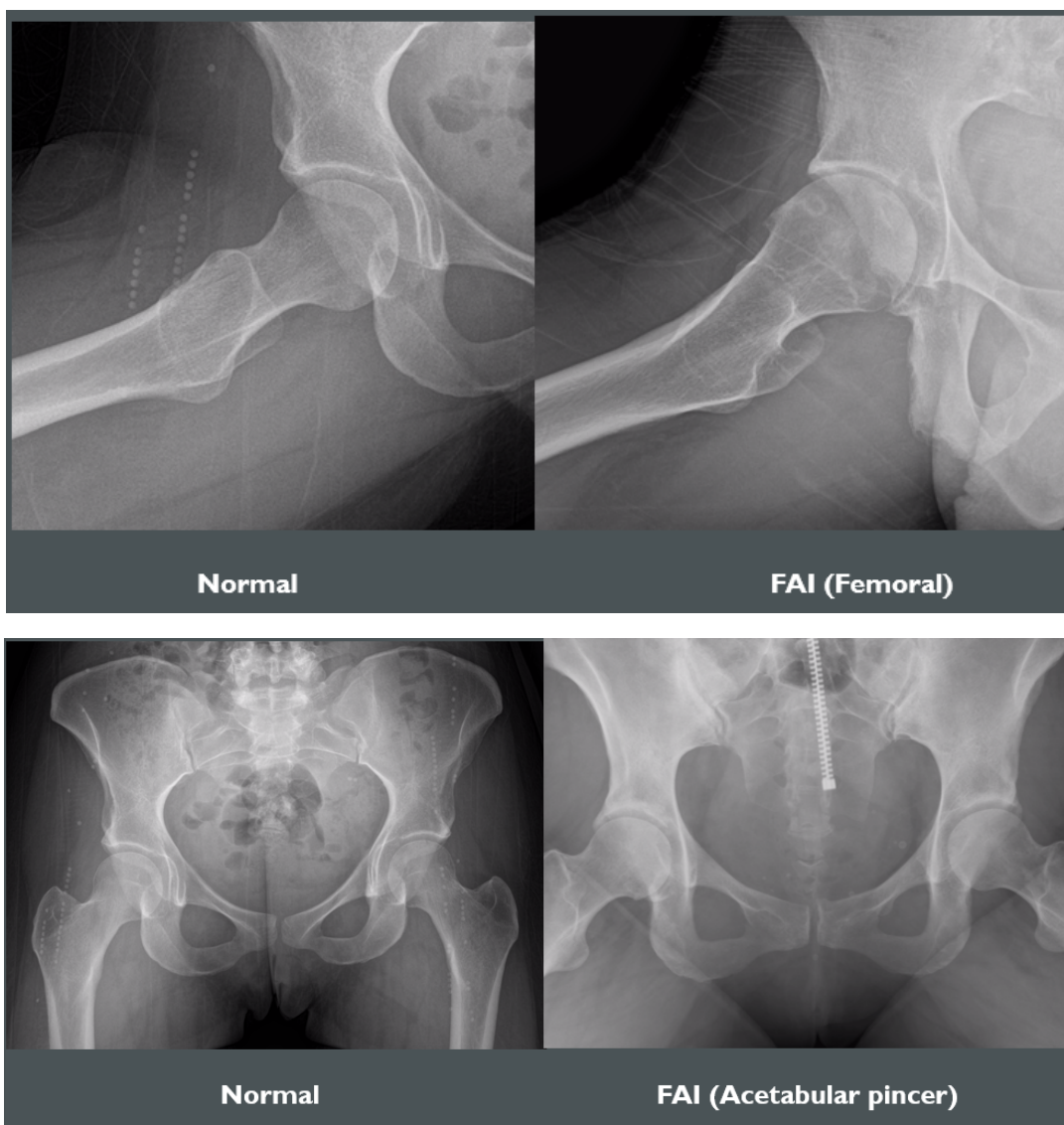
The physical exam is comprised of assessing areas of tenderness, ROM of both the injured and non injured hip, and strength. A special test for impingement involves flexion of the hip to 90 degrees, adduction of the leg across midline and internal rotation of the hip. This test often recreates the hip symptoms as this engages the femoral neck with the acetabular rim.

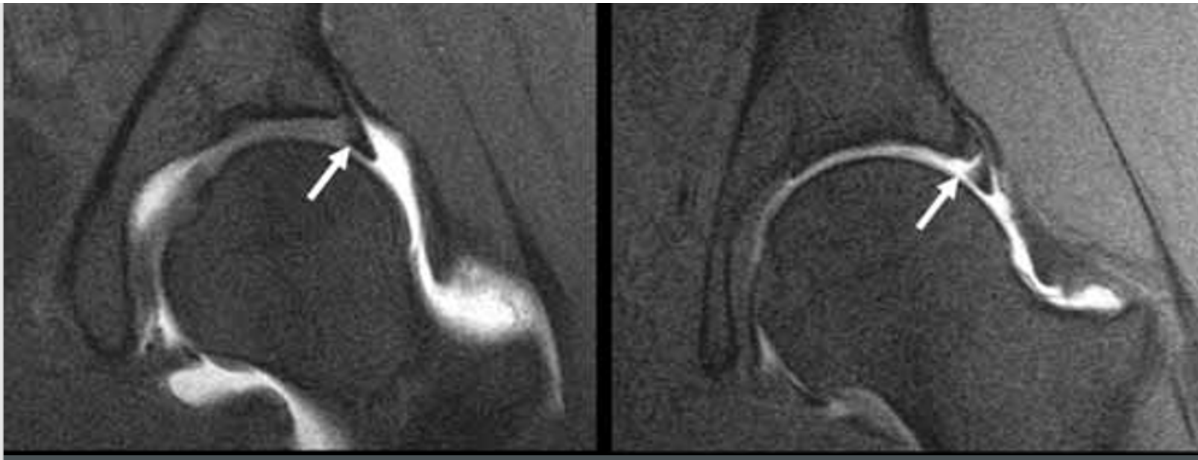
### Imaging:

X-rays are often the first imaging modality obtained. These can help assess the bony structure of the hip and pelvis, as well as assess the joint for any signs of arthritis.

If FAI or a labral tear is suspected based off of symptoms, exam, and xray findings, an MRI (or MR arthrogram) is obtained to evaluate the labrum and cartilage of the hip. An arthrogram involves injecting contrast dye into the hip joint to help illuminate the images of the MRI. Additionally, the arthrogram often includes a numbing medicine which can help to assess for pain relief inside the hip joint.

It is important to know that although an MRI may show a labral tear, not all labral tears are symptomatic. Several studies have shown that even patients WITHOUT hip pain were found to have labral tears on MRI (60-80% of asymptomatic patients have labral tears on MRI<sup>1-3</sup>). Ultimately, an MRI can show structural changes, injury, tearing etc., but it doesn't show PAIN.



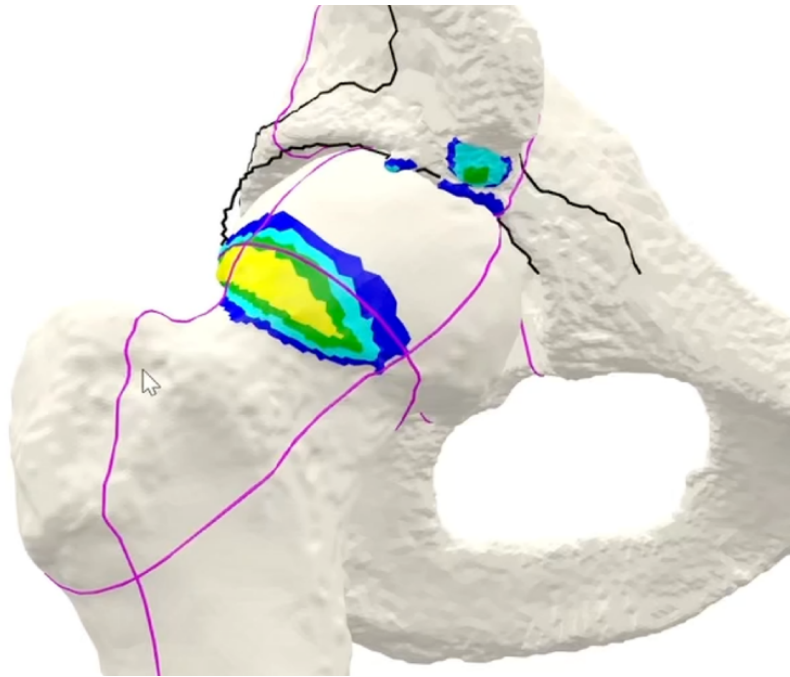


*Left image demonstrates intact labrum (arrow). Right image shows a labral tear (arrow) with separation of the labrum from the edge of the socket (i.e. acetabulum).*

**Injection:**

One way to isolate the PAIN source, is localized injections. For FAI, an injection (of numbing medicine +/- cortisone or contrast dye for arthrogram) can help to identify if the pain is coming from the hip (i.e. labrum and cartilage). For instance, if an injection is performed into the hip joint, this will numb up the labrum and cartilage of the hip. If this resolves the symptoms, even briefly, this helps to confirm the symptoms are coming from those structures. If there is no relief after the injection, there is consideration that the pain is coming from OUTSIDE the hip.

Additional imaging may include a CT scan. A CT scan can help to better characterize the bony shape and structure 3 dimensionally. These CT images can also be used with computer software to create 3D models that can show exactly where bony impingement may be occurring



*3d Hip Map of a right hip demonstrating the areas of bony impingement between the femoral neck and acetabular rim.*

## TREATMENT OPTIONS

### Non-Surgical Treatment

First line treatment for FAI is typically conservative management involving predominantly physical therapy as well as rest, activity modification and anti-inflammatory medications. Injections may be considered if these treatments fail, or to confirm the diagnosis, as mentioned above.

### Surgical Treatment

Surgical treatment is indicated when FAI continues to be symptomatic despite non surgical treatments. Surgery is performed arthroscopically, through small incisions with a camera and small instruments inserted into the hip joint. There are two main goals of surgical treatment in FAI. The first is to address the damaged portion of the hip joint. This may involve repairing or removing damaged tissue. The second is to correct or improve the abnormal shape of the hip joint.

Recovery involves a period of protected weight bearing on crutches with early physical therapy to restore motion of the hip and eventually introduce strengthening exercises to return to recreational and sporting activities.

## CITED SOURCES

### High Prevalence of Pelvic and Hip Magnetic Resonance Imaging Findings in Asymptomatic Collegiate and Professional Hockey Players

Matthew L. Silvis,<sup>\*†</sup> MD, Timothy J. Mosher,<sup>†</sup> MD, Brandon S. Smetana,<sup>†</sup> BA, Vernon M. Chinchilli,<sup>†</sup> PhD, Donald J. Flemming,<sup>†</sup> MD, Eric A. Walker,<sup>†</sup> MD, and Kevin P. Black,<sup>†</sup> MD  
*Investigation performed at Pennsylvania State Milton S. Hershey Medical Center, Hershey, Pennsylvania*

### Identification of Acetabular Labral Pathological Changes in Asymptomatic Volunteers Using Optimized, Noncontrast 1.5-T Magnetic Resonance Imaging

Matthew R. Schmitz,<sup>\*†</sup> MD, Scot E. Campbell,<sup>‡</sup> MD, Ryan S. Fajardo,<sup>§</sup> MD, and Warren R. Kadmas,<sup>†</sup> MD  
*Investigation performed at San Antonio Military Medical Center, Fort Sam Houston, Texas*

### Prevalence of Abnormal Hip Findings in Asymptomatic Participants

#### A Prospective, Blinded Study

Brad Register,<sup>\*</sup> MD, Andrew T. Pennock,<sup>†</sup> MD, Charles P. Ho,<sup>‡</sup> PhD, MD, Colin D. Strickland,<sup>§</sup> MD, Ashur Lawand,<sup>||</sup> MD, and Marc J. Philippon,<sup>†¶</sup> MD  
*Investigation performed at the Steadman Philippon Research Institute, Vail, Colorado*