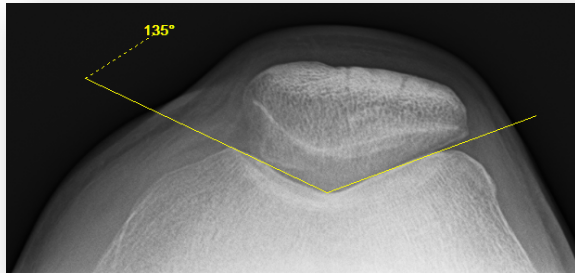


## Patellar Dislocation/Instability

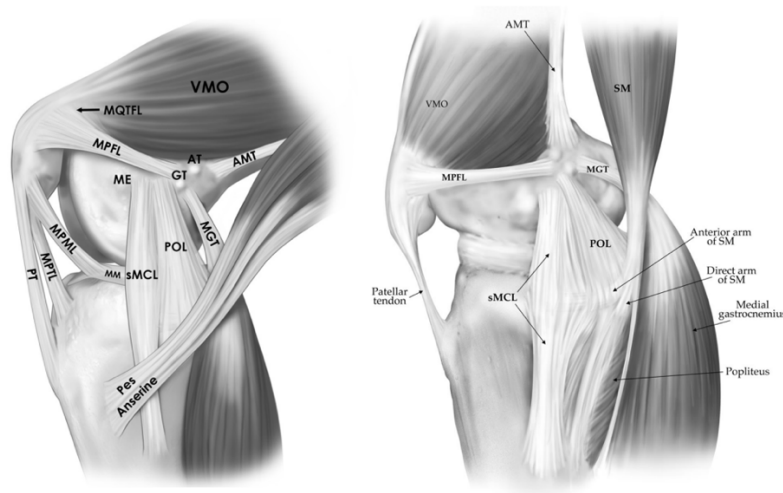
Dislocations of the patella (kneecap) are a relatively common injury in young patients and typically occur in association with sports.<sup>2</sup> Usually, a dislocation results in significant swelling in the knee and is quite painful.<sup>2</sup> A patellar dislocation is almost always lateral.

### Patellofemoral Anatomy

There are many bony and soft tissue restraints to prevent dislocation.<sup>10,17</sup> The patella is most prone to dislocation from 0 degrees (full extension) to 20 degrees. At higher angles of knee flexion, the bony trochlea helps to keep the patella engaged in the patellofemoral joint.



The medial patellofemoral ligament (MPFL) courses from the medial patella to the femur and is the primary soft tissue restraint to dislocation from 0-30 degrees.<sup>8,11</sup> The quadriceps is a dynamic stabilizer that helps to stabilize the patellofemoral joint, and there are other smaller ligaments that contribute as well. A patellar dislocation results in an injury to the MPFL by definition.



## **Is surgery necessary after a first-time dislocation?**

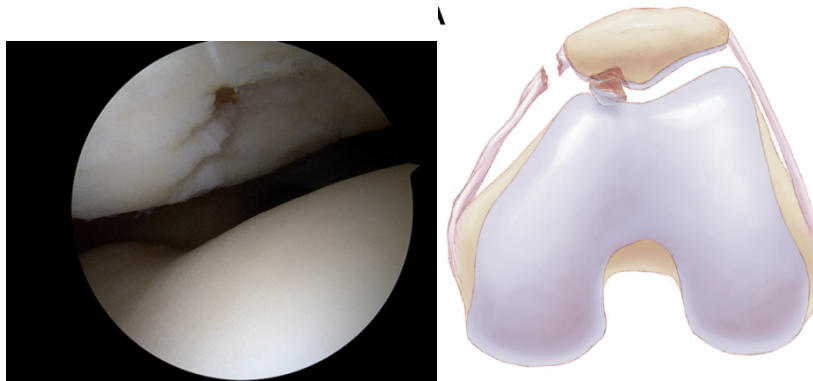After a first-time dislocation, the first step is to order an MRI to assess for any possible injury to the cartilage resulting in a “loose body.” If this MRI does not show a loose body, then generally the recommendation is for physical therapy to strengthen your quadriceps, gluteal, and core muscles. However, if there is a loose body, generally surgery is recommended to remove or reattach this loose body, and a MPFL reconstruction is recommended at the same time given the good results in the literature.<sup>3,5</sup>

Otherwise, in general, Dr. LaPrade recommends surgery after a second patellar dislocation or subluxation: “2 strikes and you’re out,” but will discuss the pros and cons with the patient and family based on the risk factors below. There are reports that the overall risk of repeat dislocation is 33%, but those with no significant risk factors have a 7-13% risk. Those with 2 or more risk factors reach 30-60% and 3+ risk factors have over a 70% chance of redislocation.<sup>6</sup>

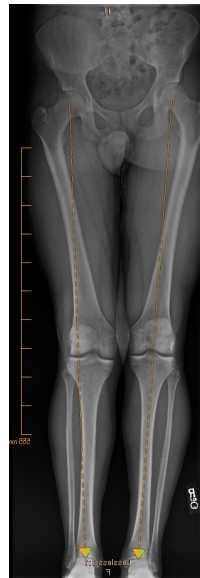## **What factors are important to consider for surgery?**

There are many important factors to ensure that the correct surgery is done to fix a patellar dislocation.

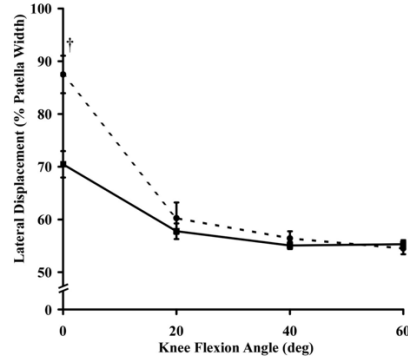
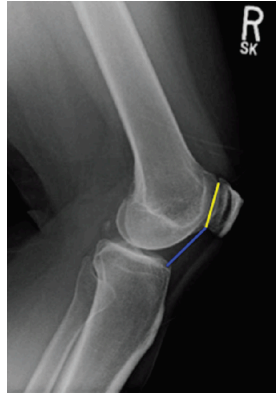1. Is the patient still growing?
  - a. If growth plates are open, generally the only option is a MPFL reconstruction
  - b. We will assess the growth plates on X-Rays in clinic
  
2. Is there any cartilage injury?
  - a. If there is injury to the cartilage with a sliver of bone attached, there may be a possibility of fixing the cartilage/bone (osteochondral) fragment
  - b. If it is only cartilage on the injured piece, this is generally not fixable and may require a cartilage transplant. There are many options for this, but in the patellofemoral joint, usually a type of autologous cartilage implantation is preferred. This may mean that two surgeries are required in order to remove the loose body and grow the cartilage for a later transplantation
  - c. We will assess for cartilage injury on the MRI



3. Are there any anatomic risk factors for recurrence?
  - a. Alignment
    - i. Patients in valgus alignment (“knock-kneed”) have increased risk of patellar dislocation
    - ii. We will get alignment X-Rays in clinic

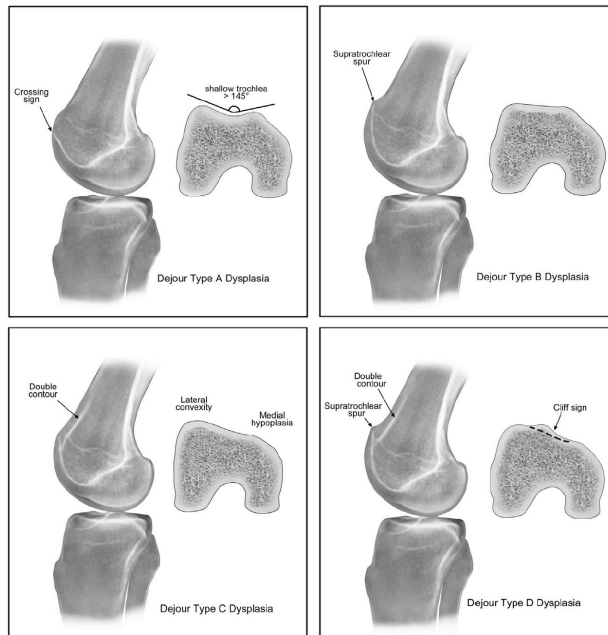


- b. Patella Alta
        - i. Patients with a higher patella can dislocate more easily because the patella is higher than the trochlear groove and therefore the bony constraint is lost<sup>9,16</sup>
        - ii. We will assess this on X-Rays in clinic



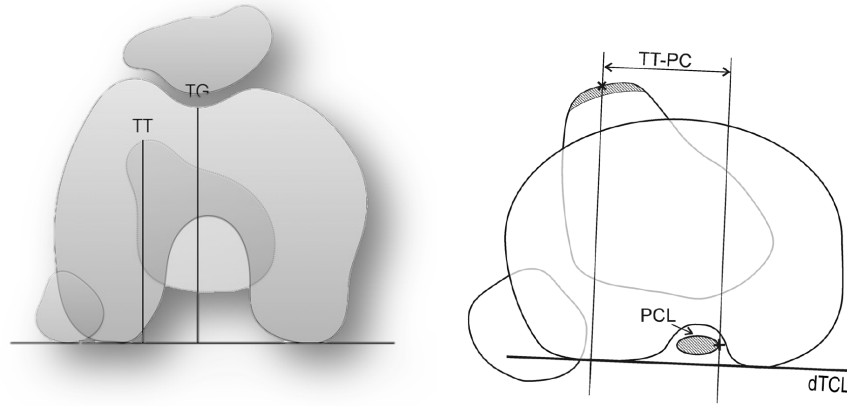
**c. Trochlear Dysplasia**

- i. This means that the trochlea does not have a normal groove and can predispose patients to failure. This can range from mild to severe<sup>10</sup>
- ii. This will be assessed on X-Rays in clinic and MRI



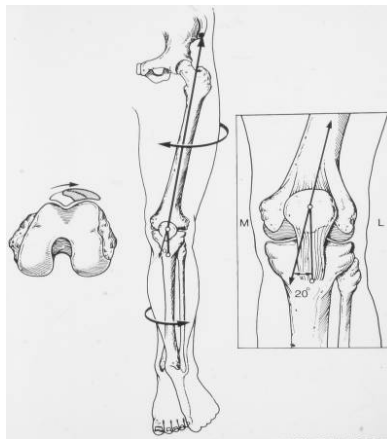
**d. Lateralization of the Tibial Tubercle**

- i. Increased lateralization may predispose a patient to patellar instability because there is increased tendency for the patella to travel laterally and potentially dislocate
- ii. Measured on CT or MRI with a TT-TG (> 20 mm = abnormal) or TT-PCL (>24 mm = abnormal)



e. Torsional Malalignment

- i. Increased femoral anteversion or external tibial torsion can increase the risk of dislocation
- ii. This will be assessed on full extremity CT if there is a concern from the physical exam



**What is a MPFL reconstruction?**

A MPFL reconstruction involves using an autograft or cadaver allograft tendon to recreate the MPFL ligament that was torn during the dislocation. This graft is secured with suture anchors to the patella and femur. A reconstruction is preferred because suture repair of the torn MPFL has been shown to do significantly worse than a reconstruction.<sup>7,12</sup> Dr. LaPrade usually recommends using a cadaver allograft reconstruction to minimize the time under anesthesia and pain after surgery. A MPFL reconstruction is utilized as a part of all patellar instability surgeries, including the larger ones described below.

Christopher M. LaPrade, MD  
Sports Medicine/Shoulder & Elbow Surgeon  
Eagan and Eden Prairie, MN  
<https://tcomn.com/physicians/christopher-laprade/>

An isolated MPFL reconstruction has been reported to have a return-to-sport rate of 95%.<sup>14</sup> Following surgery, you will be on crutches with a knee brace, but able to put weight on your leg with the leg fully straight immediately after surgery. Usually a return to sport-specific activities is around 4.5 months, with unrestricted return-to-sport around 6 months.

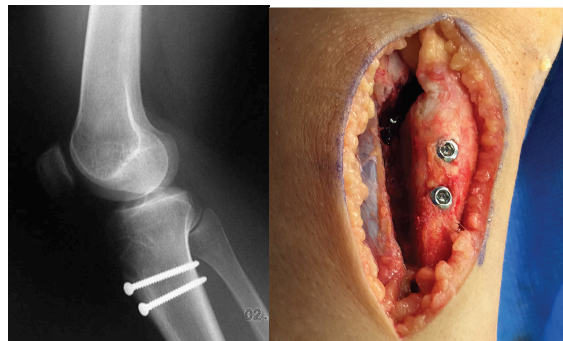
If a patient is still growing, a MPFL is the only safe surgical option. Even if a patient has multiple risk factors, there is evidence that patients can do quite well with MPFL reconstruction alone.<sup>1</sup>

### **What are Tibial Tubercle Osteotomy (TTO), lateral lengthening, and trochleoplasty procedures?**

Patients who are done growing and have multiple risk factors for repeat dislocation, cartilage injury, severe trochlear dysplasia, or a failed prior MPFL reconstruction may require more extensive surgery to address their patellar instability. All of these would be in combination with a MPFL reconstruction and possible cartilage procedure.

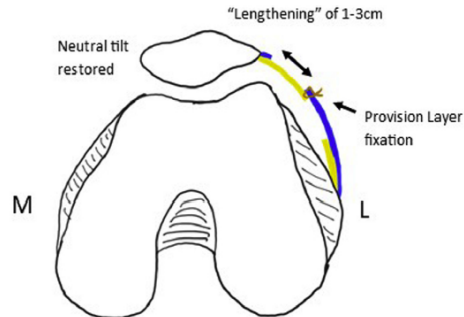
A TTO involves cutting the tibial tubercle and moving it slightly anterior and medial in order to address the increased lateralization of the tibial tubercle or a high riding patella, and it also can offload any cartilage injury to the lateral patella. It is then fixed in place with 2 or 3 screws. Occasionally, distalization will also be performed if there is significant patellar alta, but this has been reported to have more complications so generally is only performed when necessary.<sup>13</sup>

Return-to-sport rates are quite high after combined TTO and MPFL (86%).<sup>14</sup> Usually, after a TTO you will be on crutches for 6-8 weeks, and it will be 6-9 months before a full return to sports.

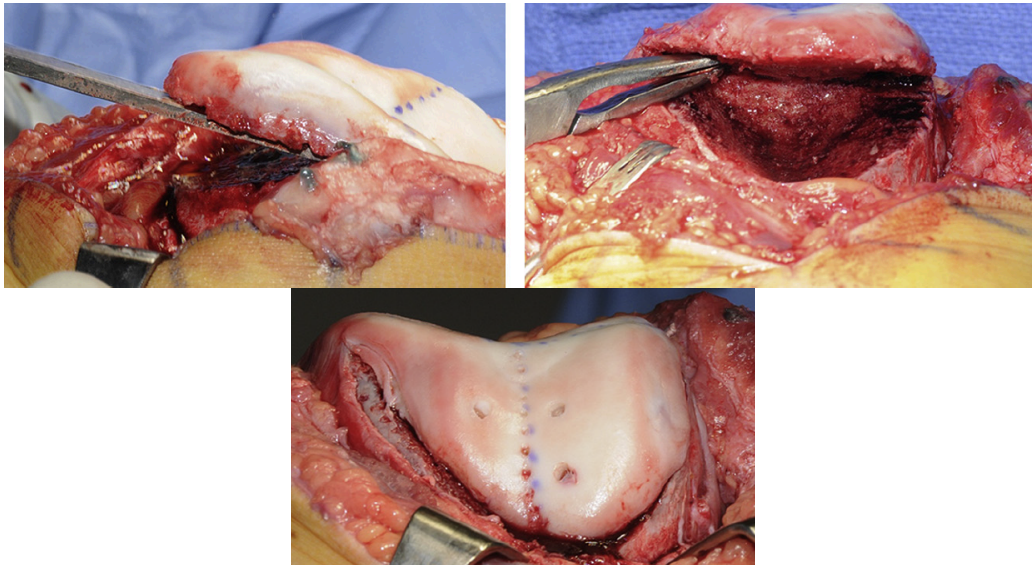


Lateral retinacular lengthening involves lengthening the tight lateral tissues to center the patella in the groove.<sup>4</sup> It does not change the rehab protocol.





A trochleoplasty is a fairly rare procedure, but when there is significant trochlear dysplasia in which a patient is lacking the normal groove of the trochlea, a trochleoplasty is an option to reshape the trochlea to change the anatomy and provide additional bony stability.<sup>10</sup> Trochleoplasty does not change the rehab protocol from a MPFL reconstruction.



### Physical Therapy Protocols

Dr. LaPrade has utmost trust in the Twin Cities Orthopedics physical therapists, who helped design the PT protocols that he uses. He will generally recommend at least one visit with them postoperatively, even if a patient will do their PT at a non-TCO location.

Christopher M. LaPrade, MD  
Sports Medicine/Shoulder & Elbow Surgeon  
Eagan and Eden Prairie, MN  
<https://tcomn.com/physicians/christopher-laprade/>

General guidelines for return-to-play for either MPFL reconstruction or TTO are listed below. The full PT protocols for isolated MPFL reconstruction and MPFL/TTO are on Dr. LaPrade’s website: <https://tcomn.com/physicians/christopher-laprade/>.

POST-KNEE SURGERY RETURN TO ACTIVITY GUIDELINES/CRITERIA	
Return to run guidelines	≥12 weeks post-op, YBT-Anterior ≤8 cm SSD, walk ≥1 mile no limp/no pain, Quad strength ≥70% LSI, ≥60% peak torque/BW
Return to jump guidelines	≥16 weeks post-op, YBT(A) ≤4 cm SSD, Quad strength ≥80% LSI, ≥80% peak torque/BW, tolerate hopping/skipping drills with no increased soreness/swelling, tolerate lunge/squat/step single leg training progressions
Return to sport guidelines	In addition to TRAC testing goals (listed below), patient must achieve the following: >6 months post-op 12+ weeks progressive strength training 8+ weeks neuromotor training program 6+ weeks within-sport practice progression (per MD/PT team clearance) 3+ weeks graduated return to competition (per MD/PT team clearance)

POST-KNEE SURGERY “TRAC” PHYSICAL PERFORMANCE TESTING - TIMELINES & GOALS <i>(Will be performed at TCO/Training HAUS in Eagan, MN)</i>			
TRAC Test Activity	4 Month Goals	7 Month Goals	10 Month Goals
Knee Extension ROM	≤5° SSD	≤0° SSD	≤0° SSD
Knee Flexion ROM	≤10° SSD	≤5° SSD	≤0° SSD
YBT(A) Squat SSD	≤8 cm SSD	≤4 cm SSD	≤4 cm SSD
<i>Max YBT(A) squat depth relative to LL</i>	≥55% of LL	≥70% of LL	≥70% of LL
Repeated single leg squat (one leg rise test)	25 reps to 60° KF	25 reps to 90° KF	25 reps to 90° KF
2 leg squat symmetry (over force plates)	≤10% off-shift	≤5% off-shift	≤5% off-shift
Hip ABD strength LSI	≥80% LSI	≥90% LSI	≥90% LSI
<i>Hip ABD strength relative to BW</i>	≥20% of BW	≥25% of BW	≥30% of BW
Quad strength LSI	≥70% LSI	≥80% LSI	≥90% LSI
<i>Quad strength relative to BW</i>	≥70% of BW	≥80% of BW	≥90% of BW
Hamstring strength LSI		≥75% LSI	≥90% LSI
Single leg hop (SLH) test LSI		≥80% LSI	≥90% LSI
<i>SLH distance relative to LL (norm comparison)</i>		≥80% of norms	≥90% of norms
Triple hop test LSI		≥80% LSI	≥90% LSI
<i>Triple hop distance (norm comparison)</i>		≥80% of norms	≥90% of norms
2 leg jump (off shift at take-off/landing)		≤20% off shift	≤10% off shift
Peak knee flexion angle SSD with hop landing		≤20° SSD	≤10° SSD

*Abbreviations for both tables above: (ABD) abduction, (BW) body weight, (ISO) isometric, (LL) leg length, (LSI) limb symmetry index, (norm) age & sex-matched normative data, (PRE) progressive resistance exercise, (ROM) range of motion, (SLR) straight leg raise, (SSD) side to side difference, (TRAC) testing to return to athletic competition, (UE) upper extremity, (YBT(A)) Y-balance test anterior reach*



Christopher M. LaPrade, MD  
Sports Medicine/Shoulder & Elbow Surgeon  
Eagan and Eden Prairie, MN  
<https://tcomn.com/physicians/christopher-laprade/>

## References

1. Dennis ER, Marmor WA, Propp BE, Erickson BJ, Gruber S, Brady JM, Nguyen JT, Shubin Stein BE. Isolated Medial Patellofemoral Ligament Reconstruction for Recurrent Patellar Instability Regardless of Tibial Tubercle-Trochlear Groove Distance and Patellar Height: Minimum 5-Year Outcomes. *Am J Sports Med.* 2024 Jul;52(9):2196-2204. PMID: 39101725.
2. Fithian DC, Paxton EW, Stone ML, Silva P, Davis DK, Elias DA, White LM. Epidemiology and natural history of acute patellar dislocation. *Am J Sports Med.* 2004 Jul-Aug;32(5):1114-21. PMID: 15262631.
3. Gurusamy P, Pedowitz JM, Carroll AN, Johnson K, Chambers HG, Edmonds EW, Pennock AT. Medial Patellofemoral Ligament Reconstruction for Adolescents With Acute First-Time Patellar Dislocation With an Associated Loose Body. *Am J Sports Med.* 2021 Jul;49(8):2159-2164. PMID: 34097530.
4. Hayden DJ, Doshi C, Parikh SN. Lateral Patellar Retinaculum Z-Lengthening. *Arthrosc Tech.* 2021 Jun 28;10(7):e1883-e1887. PMID: 34336590
5. Hinckel B, Smith J, Tanaka MJ, Matsushita T, Martinez-Cano JP. Patellofemoral instability part 1 (When to operate and soft tissue procedures): State of the art. *J ISAKOS.* 2024 May 23:S2059-7754(24)00100-7.. PMID: 38795864.
6. Huntington LS, Webster KE, Devitt BM, Scanlon JP, Feller JA. Factors Associated With an Increased Risk of Recurrence After a First-Time Patellar Dislocation: A Systematic Review and Meta-analysis. *Am J Sports Med.* 2020 Aug;48(10):2552-2562. PMID: 31825650.
7. Hurley ET, Colasanti CA, Anil U, McAllister D, Matache BA, Alaia MJ, Strauss EJ, Campbell KA. Management of Patellar Instability: A Network Meta-analysis of Randomized Control Trials. *Am J Sports Med.* 2022 Jul;50(9):2561-2567. 34339311.
8. Kruckeberg BM, Chahla J, Moatshe G, Cinque ME, Muckenhirn KJ, Godin JA, Ridley TJ, Brady AW, Arendt EA, LaPrade RF. Quantitative and Qualitative Analysis of the Medial Patellar Ligaments: An Anatomic and Radiographic Study. *Am J Sports Med.* 2018 Jan;46(1):153-162. PMID: 29016187.
9. Laidlaw MS, Diduch DR. Current Concepts in the Management of Patellar Instability. *Indian J Orthop.* 2017 Sep-Oct;51(5):493-504. PMID: 28966372
10. LaPrade RF, Cram TR, James EW, Rasmussen MT. Trochlear dysplasia and the role of trochleoplasty. *Clin Sports Med.* 2014 Jul;33(3):531-45. PMID: 24993414.
11. LaPrade RF, Engebretsen AH, Ly TV, Johansen S, Wentorf FA, Engebretsen L. The anatomy of the medial part of the knee. *J Bone Joint Surg Am.* 2007 Sep;89(9):2000-10. PMID: 17768198.
12. Murray IR, LaPrade CM, Pullen WM, Sherman SL. Medial Patellofemoral Ligament Repair or Medial Advancement: Is there a role? *Clin Sports Med.* 2022 Jan;41(1):157-169. PMID: 34782072
13. Payne J, Rimmke N, Schmitt LC, Flanigan DC, Magnussen RA. The Incidence of Complications of Tibial Tubercle Osteotomy: A Systematic Review. *Arthroscopy.* 2015 Sep;31(9):1819-25. PMID: 25980400.
14. Platt BN, Bowers LC, Magnuson JA, Marx SM, Liu JN, Farr J, Stone AV. Return to Sport After Medial Patellofemoral Ligament Reconstruction: A Systematic Review and Meta-analysis. *Am J Sports Med.* 2022 Jan;50(1):282-291. PMID: 33720789.
15. Tecklenburg K, Dejour D, Hoser C, Fink C. Bony and cartilaginous anatomy of the patellofemoral joint. *Knee Surg Sports Traumatol Arthrosc.* 2006 Mar;14(3):235-40. PMID: 16254736.
16. Ward SR, Terk MR, Powers CM. Patella alta: association with patellofemoral alignment and changes in contact area during weight-bearing. *J Bone Joint Surg Am.* 2007 Aug;89(8):1749-55. PMID: 17671014.